



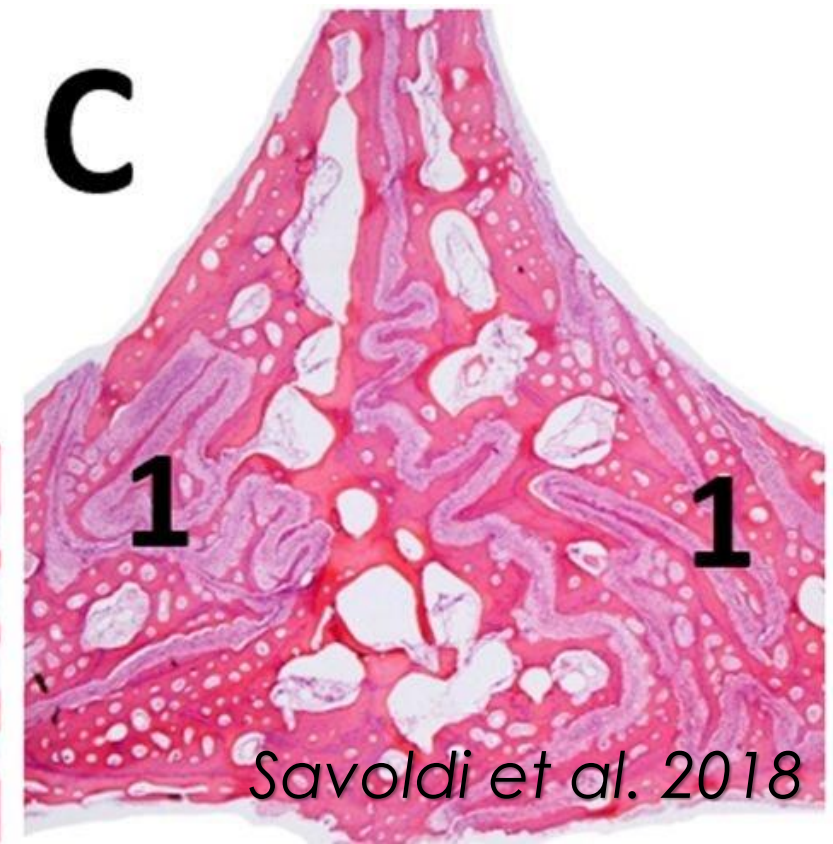
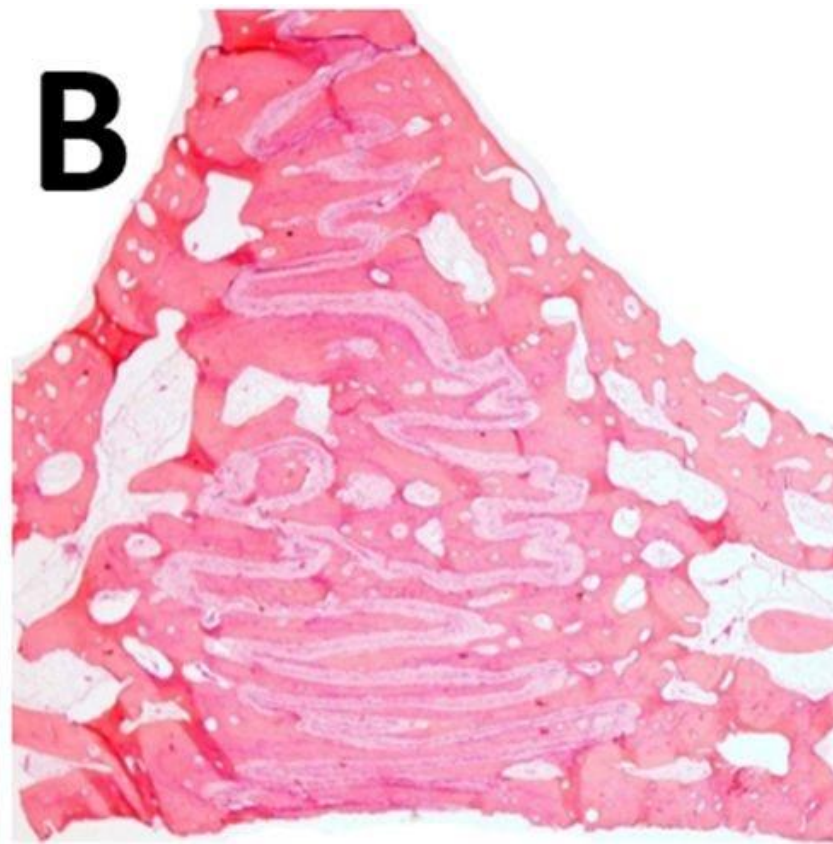
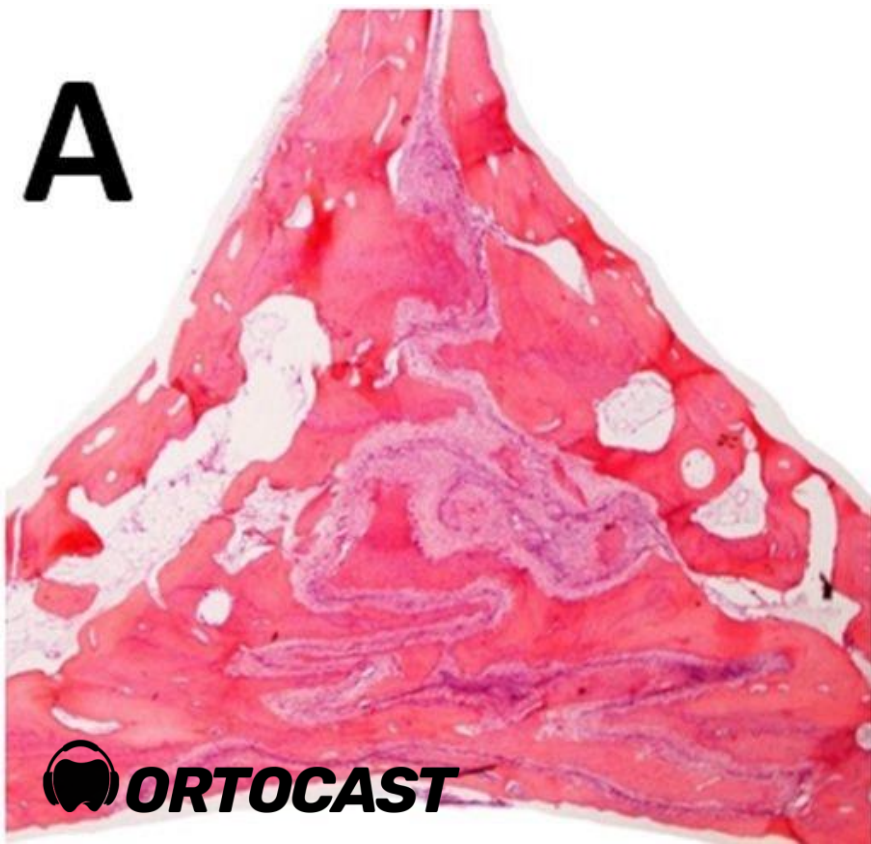# #069 MARPE

Quando usar?



**Não há** evidências concretas que demonstrem que a sutura palatina mediana esteja **completamente fusionada** ao final do crescimento facial.

*Bruneto et al. 2017*



# Maturação da Sutura Palatina Mediana

TECHNO BYTES

AJO-DO

Midpalatal suture maturation: Classification method for individual assessment before rapid maxillary expansion

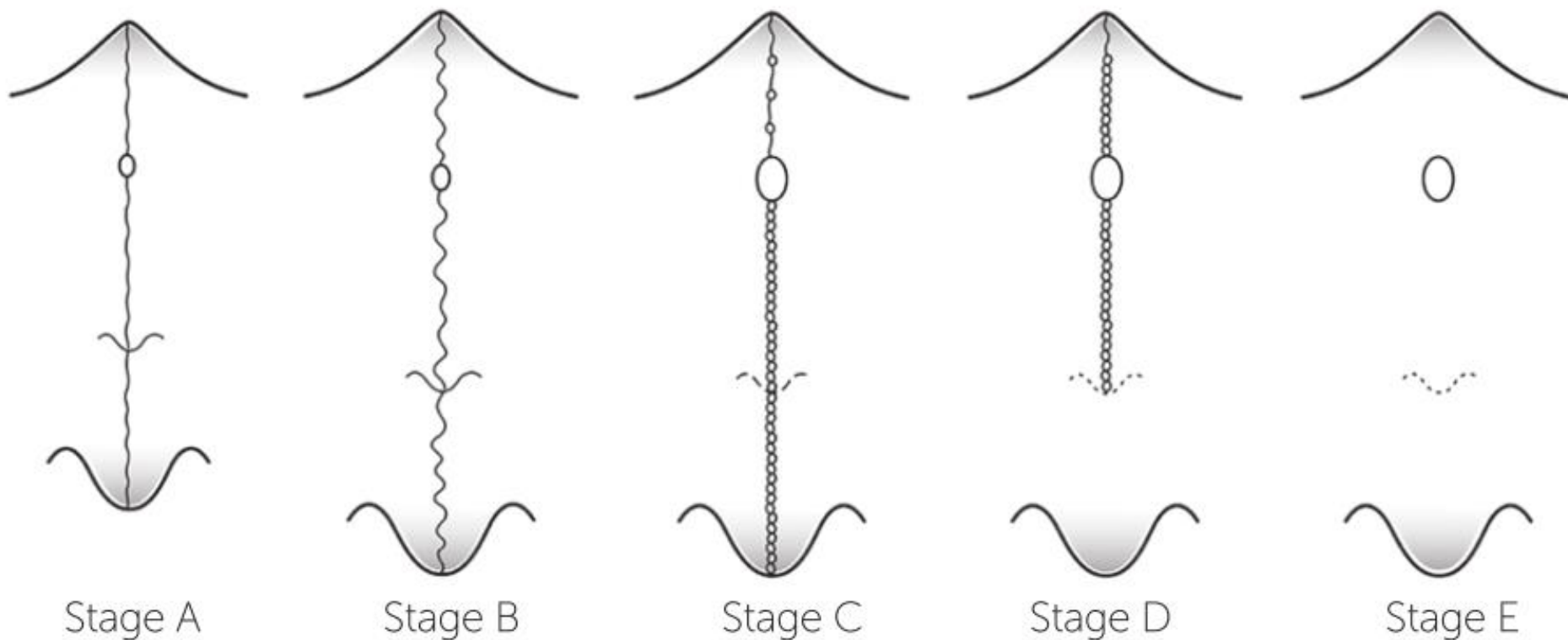
Fernanda Angelieri,<sup>a</sup> Lucia H. S. Cevidanes,<sup>b</sup> Lorenzo Franchi,<sup>c</sup> João R. Gonçalves,<sup>d</sup> Erika Benavides,<sup>e</sup> and James A. McNamara Jr<sup>f</sup>

*São Paulo and Araraquara, Brazil, Ann Arbor, Mich, and Florence, Italy*

*Angelieri et al. 2013*

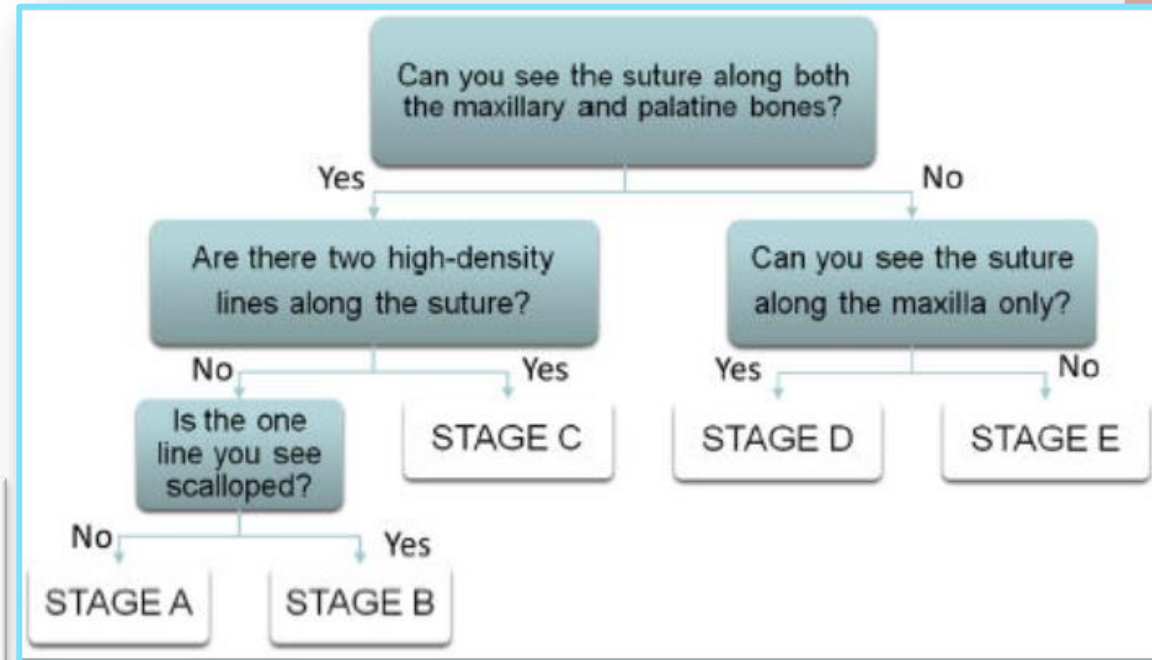
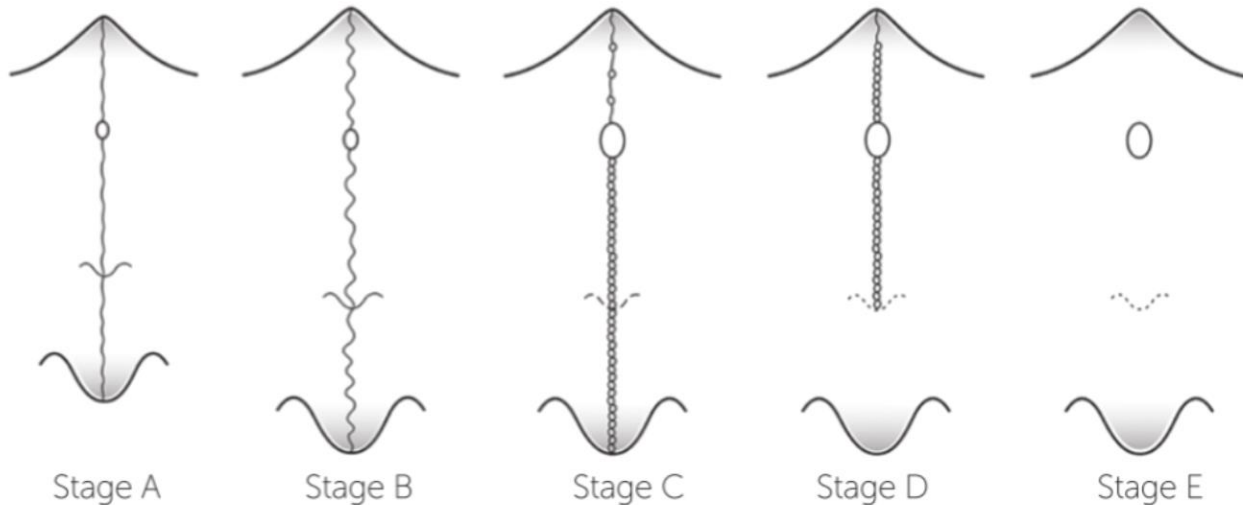
# Maturação da Sutura Palatina Mediana

*Angelieri et al. 2013*



# Maturação da Sutura Palatina Mediana

*Angelieri et al. 2013*



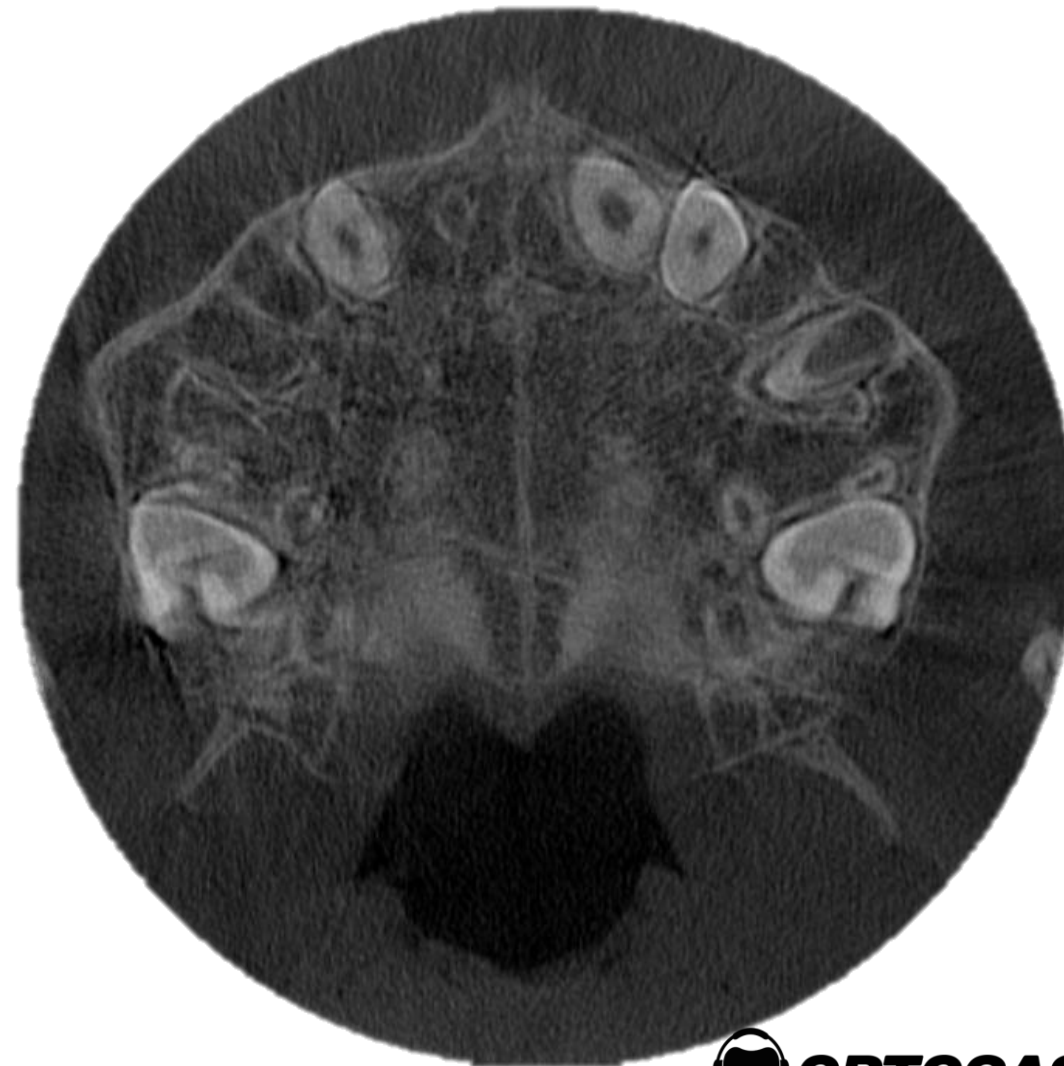

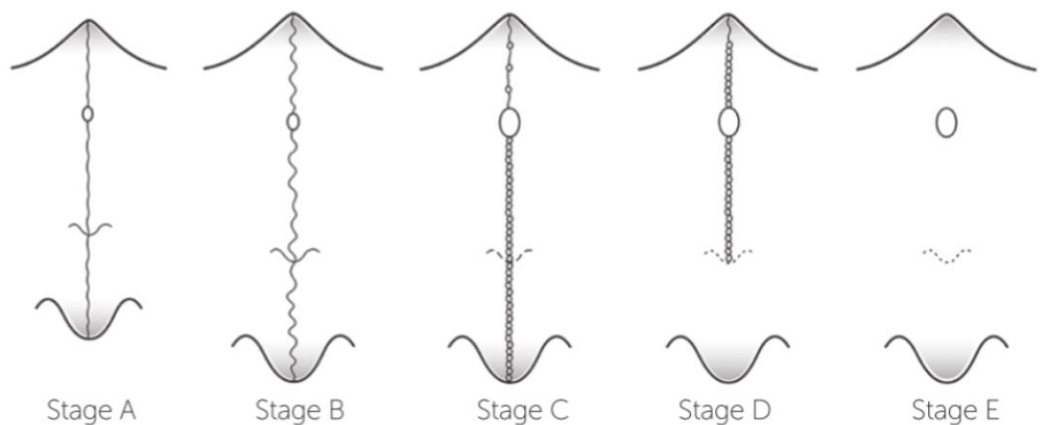
# Maturação da Sutura

## Palatina Mediana

*Angelieri et al. 2013*

### Estágio A

- . Presença de sutura em osso maxilar e palatino;
- . Sutura formada por uma linha hiperdensa;
- . Linha de sutura quase retilínea.



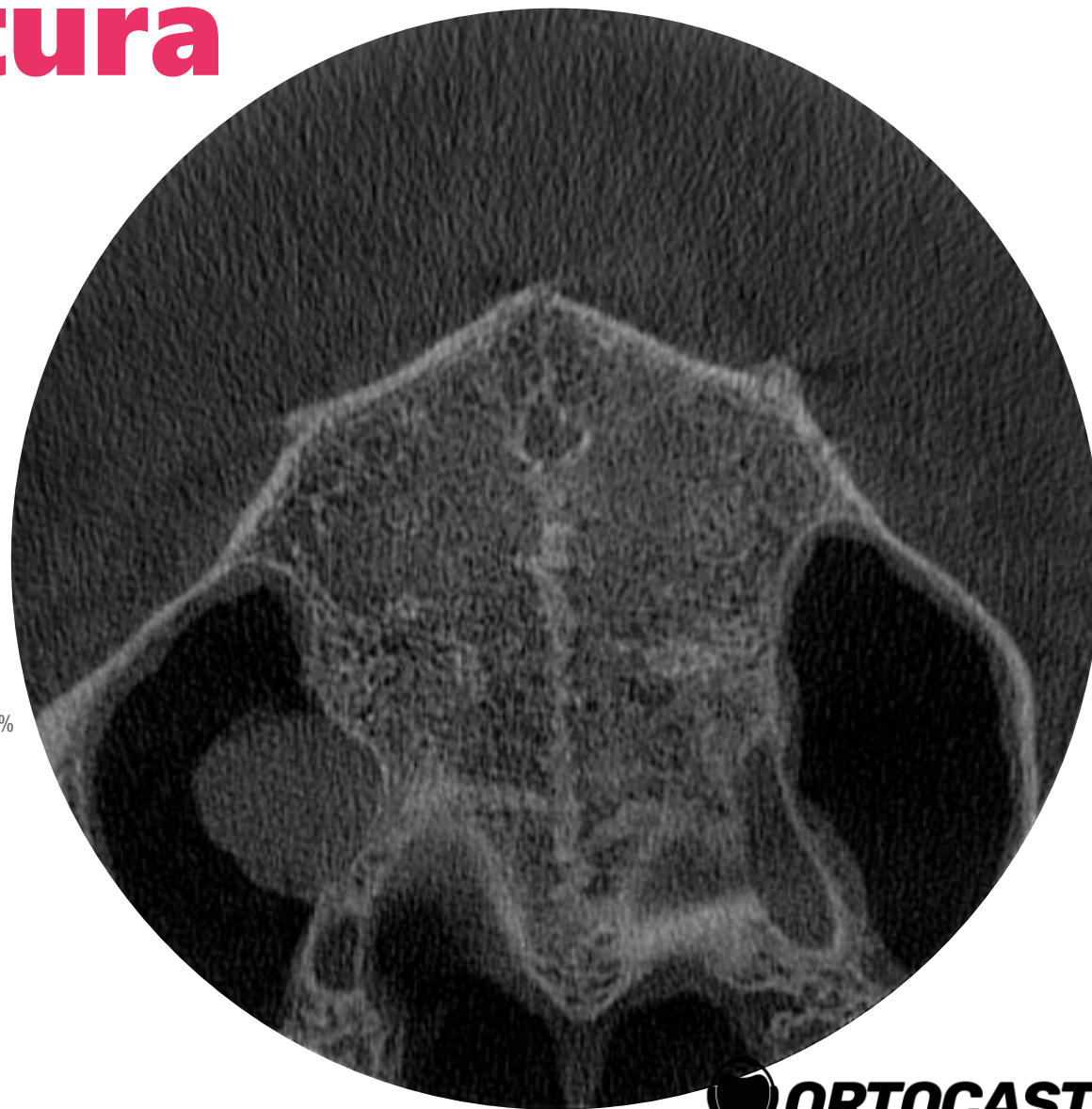

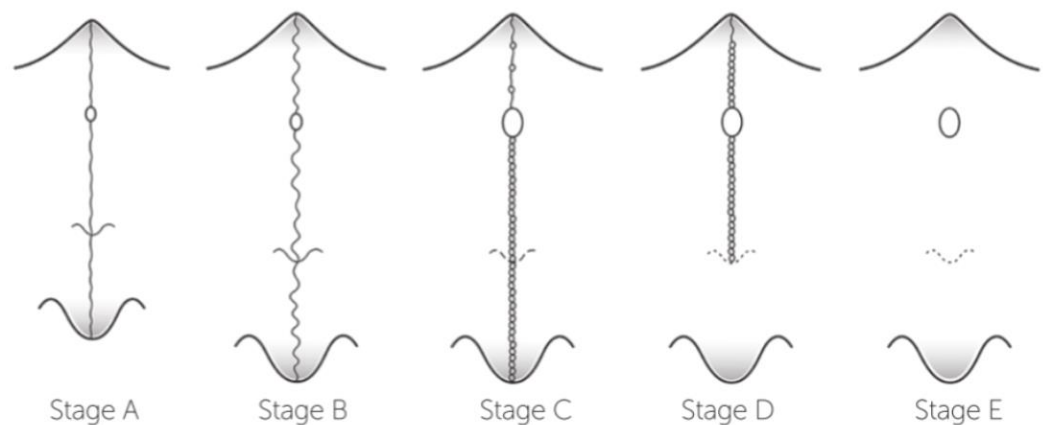
# Maturação da Sutura

## Palatina Mediana

*Angelieri et al. 2013*

### Estágio B

- . Presença de sutura em osso maxilar e palatino;
- . Sutura formada por uma linha hiperdensa;
- . Linha de sutura em sucessivas curvas (zigue-zague).



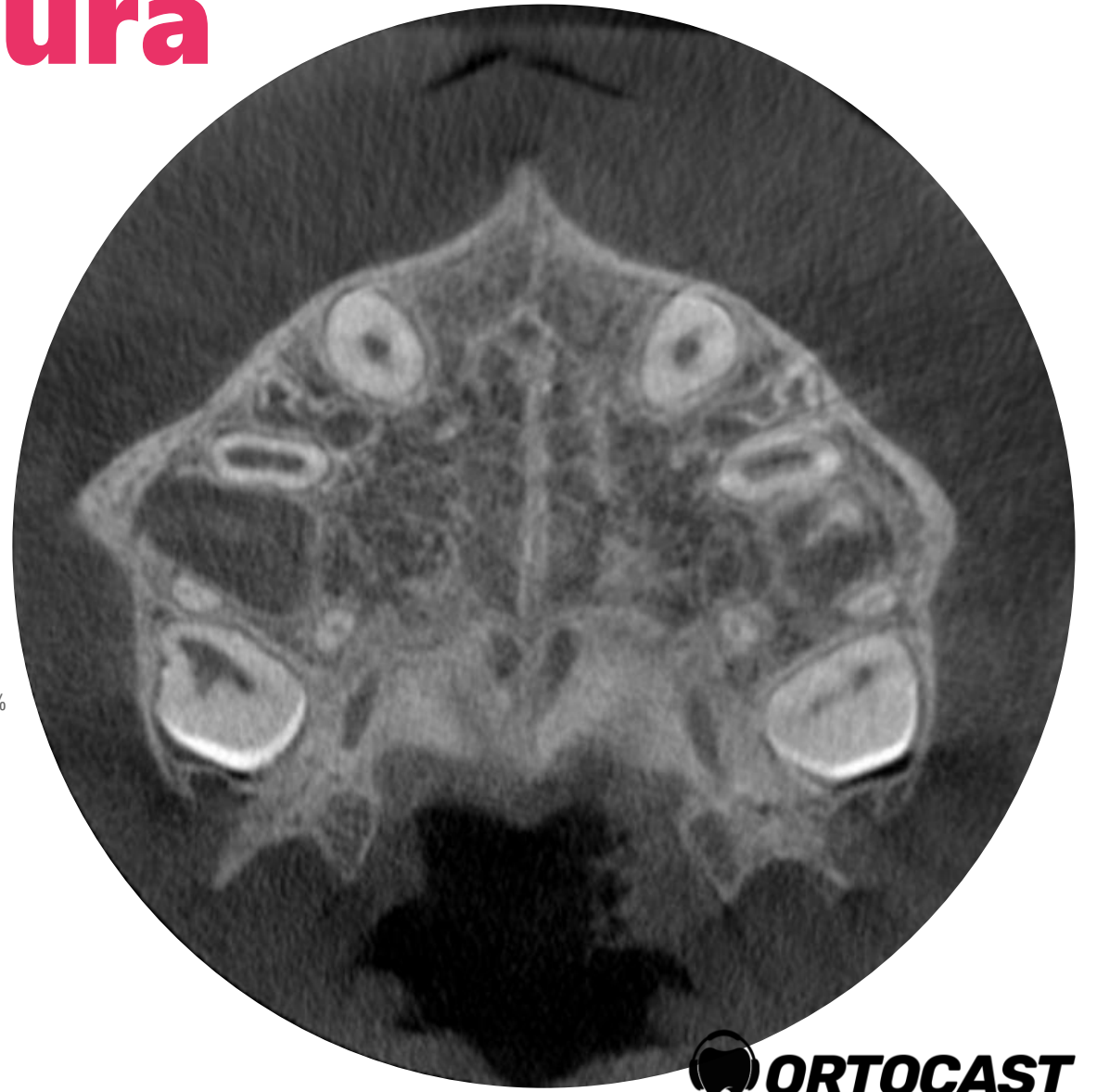
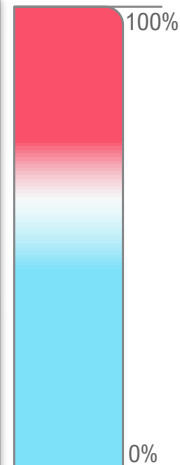
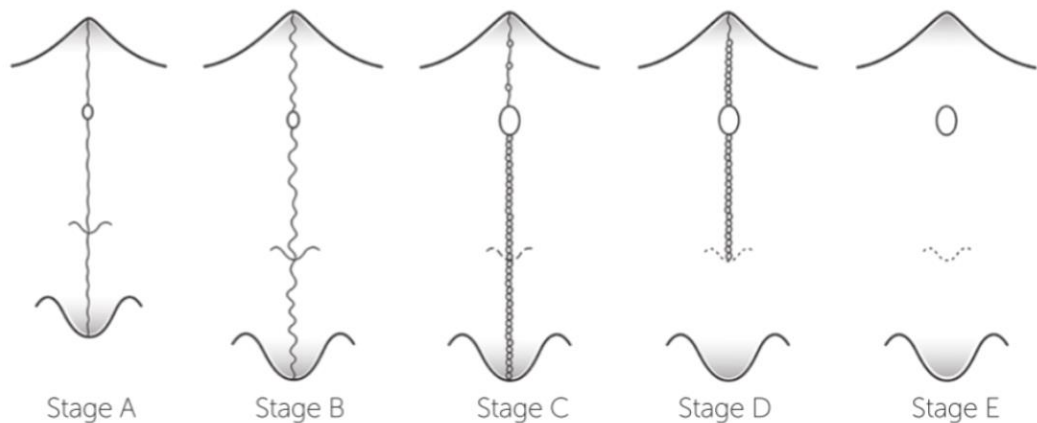
# Maturação da Sutura

## Palatina Mediana

Angelier et al. 2013

### Estágio C

- . Presença de sutura em osso maxilar e palatino;
- . Duas linhas hiperdensas ao longo da sutura.





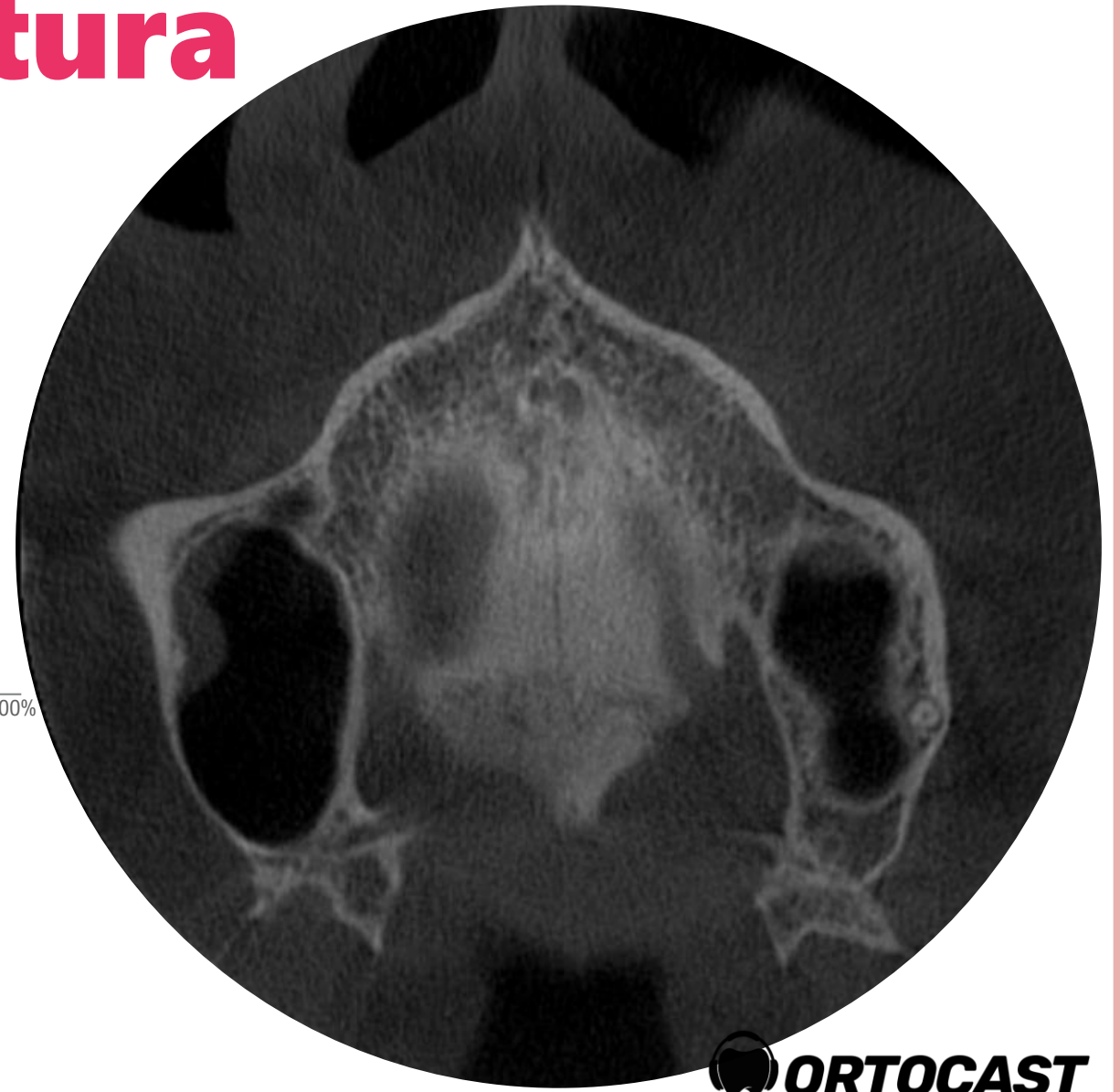

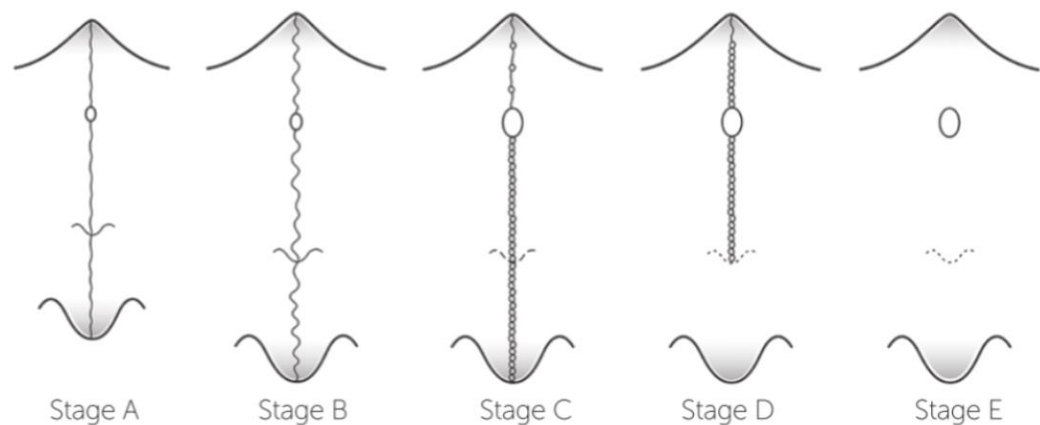
# Maturação da Sutura

## Palatina Mediana

*Angelier et al. 2013*

### Estágio D

- . Presença de sutura APENAS em osso MAXILAR;
- . Duas linhas hiperdensas ao longo da sutura.



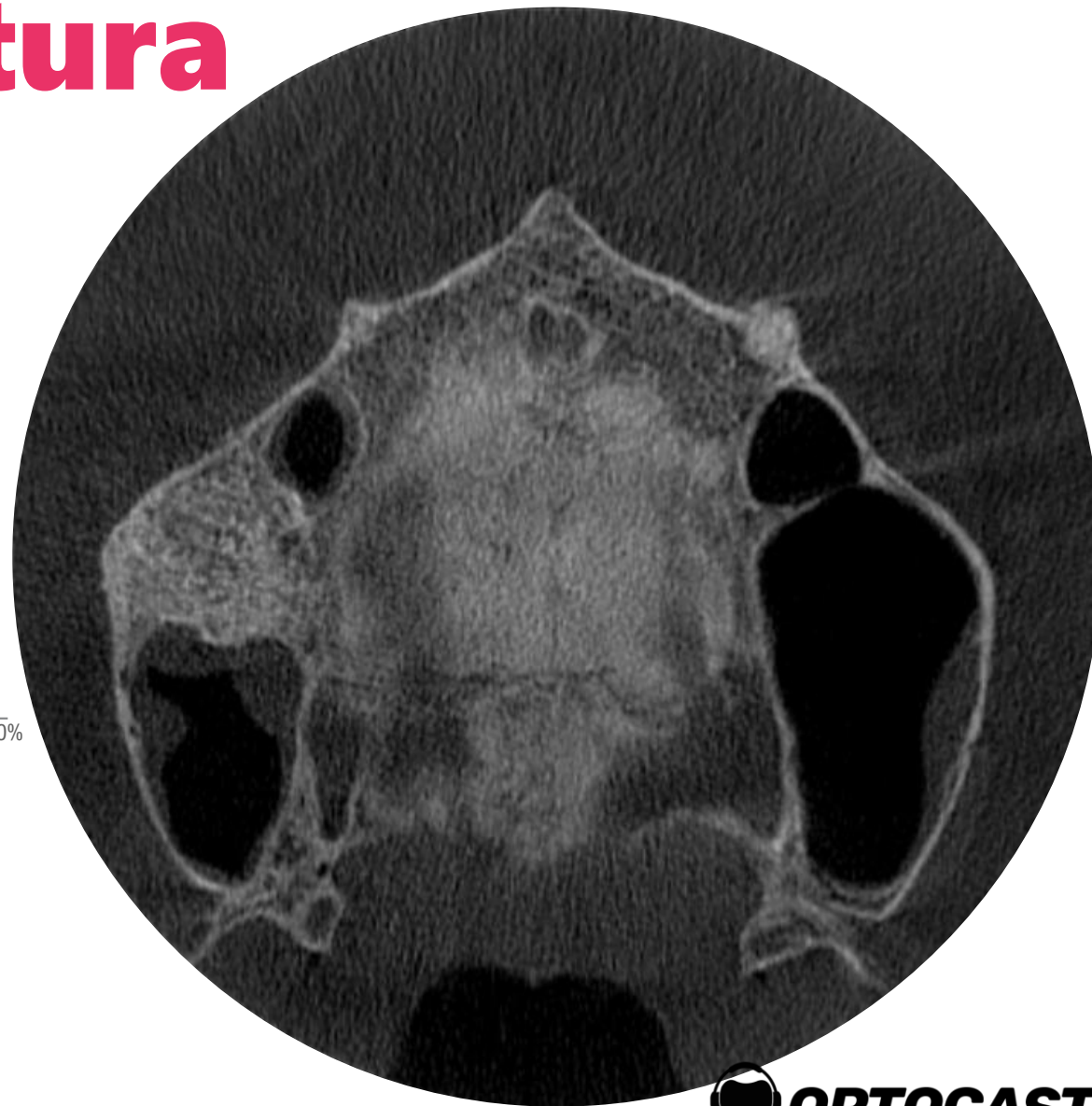

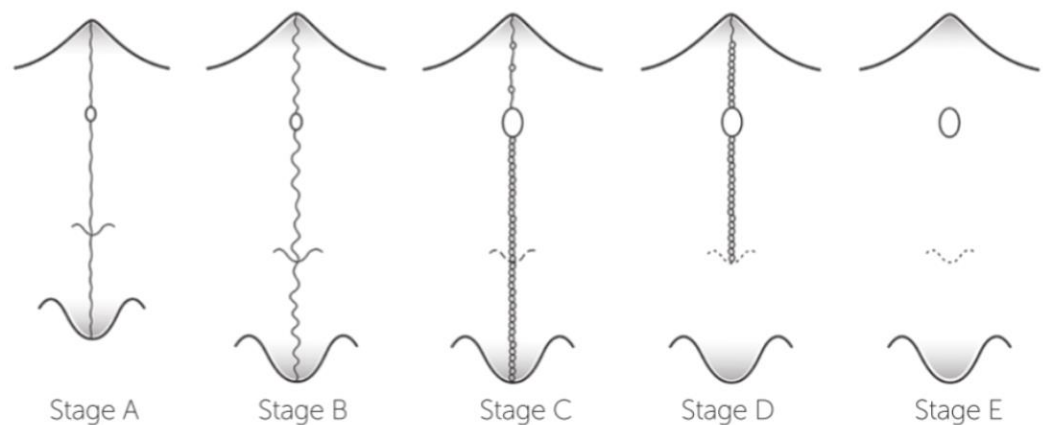
# Maturação da Sutura

## Palatina Mediana

Angelieri et al. 2013

### Estágio E

. NÃO HÁ presença de sutura em pelo menos UMA porção da maxila.



# Maturação da Sutura

## Palatina Mediana

Angelier et al. 2013

### RESUMO

Estágio A – Expansão OK

Estágio B – Expansão OK

Estágio C – Pouco Efeito Esquelético

Estágio D – Pouco Efeito Esquelético Ant.

Estágio E – Sem Efeito Esquelético

